

Adomas Bunevicius, MD, PhD^{1b*}
 Rithika Kormath Anand*
 Mohanad Suleiman, MD*
 Ahmed M. Nabeel, MD, PhD^{‡§}
 Wael A. Reda, MD, PhD^{‡¶}
 Sameh R. Tawadros, MD, PhD^{‡¶}
 Khaled Abdelkarim, MD, PhD^{‡||}
 Amr M. N. El-Shehaby, MD, PhD^{‡¶}
 Reem M. Emad, MD, PhD^{‡#}
 Tomas Chytka, MD**
 Roman Liscak, MD**
 Kimball Sheehan*
 Darrah Sheehan*
 Marco Perez Caceres^{‡#}
 David Mathieu, MD^{‡#}
 Cheng-chia Lee, MD, PhD^{§§¶¶}
 Huai-che Yang, MD^{§§¶¶}
 Piero Picozzi, MD^{||||}
 Andrea Franzini, MD^{||||}
 Luca Attuati, MD^{||||}
 Herwin Speckter, MSc^{##}
 Jeremy Olivo, MD^{##}
 Samir Patel, MD***
 Christopher P. Cifarelli, MD,
 PhD^{‡‡§§}
 Daniel T. Cifarelli, MDMS^{‡‡‡}
 Joshua D. Hack, MS^{§§§}
 Ben A. Strickland, MD^{¶¶¶}
 Gabriel Zada, MD^{¶¶¶}
 Eric L. Chang, MD, FASTRO^{|||||}
 Kareem R. Fakhoury, MD^{###}
 Chad G. Rusthoven, MD^{###}
 Ronald E. Warnick, MD****
 Jason Sheehan, MD, PhD*

*Department of Neurosurgery, University of Virginia, Charlottesville, Virginia;
 ‡Gamma Knife Center Cairo, Nasser Institute Hospital, Cairo, Egypt;
 (Continued on next page)

Correspondence:

Jason Sheehan, MD, PhD,
 Department of Neurosurgery,
 University of Virginia Health System,
 1221 Lee St.,
 Charlottesville, VA 22908, USA.
 Email: jsheehan@virginia.edu

Received, June 19, 2020.

Accepted, October 10, 2020.

© Congress of Neurological Surgeons
 2021. All rights reserved.
 For permissions, please e-mail:
journals.permissions@oup.com

Stereotactic Radiosurgery for Periopic Meningiomas: An International, Multicenter Study

BACKGROUND: Stereotactic radiosurgery (SRS) is increasingly used for management of periopic meningiomas.

OBJECTIVE: To study the safety and effectiveness of SRS for periopic meningiomas.

METHODS: From 12 institutions participating in the International Radiosurgery Research Foundation (IRRF), we retrospectively assessed treatment parameters and outcomes following SRS for meningiomas located within 3 mm of the optic apparatus.

RESULTS: A total of 438 patients (median age 51 yr) underwent SRS for histologically confirmed (29%) or radiologically suspected (71%) periopic meningiomas. Median treatment volume was 8.01 cm³. Median prescription dose was 12 Gy, and median dose to the optic apparatus was 8.50 Gy. A total of 405 patients (93%) underwent single-fraction SRS and 33 patients (7%) underwent hypofractionated SRS. During median imaging follow-up of 55.6 mo (range: 3.15–239 mo), 33 (8%) patients experienced tumor progression. Actuarial 5-yr and 10-yr progression-free survival was 96% and 89%, respectively. Prescription dose of ≥ 12 Gy (HR: 0.310; 95% CI [0.141–0.679], $P = .003$) and single-fraction SRS (HR: 0.078; 95% CI [0.016–0.395], $P = .002$) were associated with improved tumor control. A total of 31 (10%) patients experienced visual decline, with actuarial 5-yr and 10-yr post-SRS visual decline rates of 9% and 21%, respectively. Maximum dose to the optic apparatus ≥ 10 Gy (HR = 2.370; 95% CI [1.086–5.172], $P = .03$) and tumor progression (HR = 4.340; 95% CI [2.070–9.097], $P < .001$) were independent predictors of post-SRS visual decline.

CONCLUSION: SRS provides durable tumor control and quite acceptable rates of vision preservation in periopic meningiomas. Margin dose of ≥ 12 Gy is associated with improved tumor control, while a dose to the optic apparatus of ≥ 10 Gy and tumor progression are associated with post-SRS visual decline.

KEY WORDS: Periopic meningioma, Stereotactic radiosurgery, Gamma Knife, Outcomes, Progression-free survival, Visual outcomes

Neurosurgery 0:1–10, 2021

DOI:10.1093/neuros/nyaa544

www.neurosurgery-online.com

Management of meningiomas residing in close spatial proximity to the optic apparatus (ie, periopic meningiomas) remains challenging.^{1–5} Microsurgical and/or endoscopic tumor resection and decompression of the optic apparatus have been traditionally

considered the primary treatment option for most periopic meningiomas.^{1,6–8} However, due to close proximity to the optic nerves, infiltrative growth, and invasion of the skull base dura and cavernous sinus, resection of periopic lesions can be a technically challenging procedure even in experienced hands, and is associated with high risk of visual impairment.^{2,6,9–12}

Radiosurgery is often considered for treatment of residual skull base meningiomas.^{13,14} Radiosurgery is also increasingly used as upfront treatment for patients who are not optimal surgical candidates, perhaps due to advanced age and/or serious medical comorbidities. Stereotactic radiosurgery (SRS) is associated with high

ABBREVIATIONS: BED, biologically effective dose; CI, confidence interval; EBRT, External Beam Radiation Therapy; HR, hazard ratio; MRI, magnetic resonance imaging; PFS, progression-free survival; SRS, stereotactic radiosurgery

Neurosurgery Speaks! Audio abstracts available for this article at www.neurosurgery-online.com.

and sustained local tumor control rates of skull base meningiomas that often exceed 90%.^{15,16} However, sensitivity of the anterior visual pathway to radiation is the major limiting factor that often precludes safe delivery of radiosurgery to lesions located in close spatial proximity (usually within 3 mm) to the optic nerves. The risk for developing optic neuropathy after radiosurgery is dose-dependent, and cumulative radiation dose to the optic nerves and chiasm should not exceed 8 to 12 Gy in a single fraction.¹⁷⁻¹⁹ Fractionated SRS allows an increase in the radiation tolerance of the cumulative dosing to the optic apparatus.^{7,13,20} Single-fraction SRS has an established effectiveness and safety profile for management of perioptic tumors, including pituitary adenomas,²¹ optic pathway and hypothalamic gliomas,²² orbital apex tumors,²³ and clinoid, sellar, and parasellar meningiomas.^{24,25} Hence, the aim of this multicentered study was to evaluate safety and effectiveness of SRS for the management of perioptic meningiomas.

METHODS

Patients and Setting

A total of 438 patients were identified from 12 institutions affiliated with the International Radiosurgery Research Foundation (IRRF). The study inclusion criteria were diagnosis of meningiomas based on magnetic resonance imaging (MRI) or histological examination, meningiomas located 3 mm or closer to the optic nerve or chiasm, and treatment using single-session or hypofractionated SRS. Patients with histories of fractionated radiation therapy for an index lesion were allowed in the study. Data collection was approved by institutional review boards at each of the participating centers. Due to retrospective design, informed consents were not obtained. MRI imaging features of meningiomas included extra-axial location, dural involvement, and avid enhancement after gadolinium administration.

Clinical Assessment

We gathered information regarding patient gender, presenting symptoms, age at diagnosis, pre-SRS functional status, ophthalmological

(Continued from previous page)

⁵Neurosurgery Department, Benha University, Qalubya, Egypt; ⁶Neurosurgery Department, Ain Shams University, Cairo, Egypt; ⁷Clinical Oncology Department, Ain Shams University, Cairo, Egypt; ⁸Radiation Oncology Department, National Cancer Institute, Cairo University, Giza, Egypt; ⁹Stereotactic and Radiation Neurosurgery Department, Na Homolce Hospital, Prague, Czech Republic; ¹⁰Department of Neurosurgery, Université de Sherbrooke, Centre de recherche du CHUS, Sherbrooke, Québec, Canada; ¹¹Department of Neurosurgery, Neurological Institute, Taipei Veteran General Hospital, Taipei, Taiwan; ¹²School of Medicine, National Yang-Ming University, Taipei, Taiwan; ¹³Department of Neurosurgery, Humanitas Clinical and Research Center – IRCCS, Milan, Italy; ¹⁴Centro Gamma Knife Dominicano and CEDIMAT Radiology Department, Santo Domingo, Dominican Republic; ¹⁵Division of Radiation Oncology, Department of Oncology, University of Alberta, Edmonton, Canada; ¹⁶Department of Neurosurgery, West Virginia University, Morgantown, West Virginia; ¹⁷Department of Radiation Oncology, West Virginia University, Morgantown, West Virginia; ¹⁸Department of Neurosurgery, University of Southern California, Los Angeles, California; ¹⁹Department of Radiation Oncology, University of Southern California, Los Angeles, California; ²⁰Department of Radiation Oncology, University of Colorado, Denver, Colorado; ²¹Gamma Knife Center, Jewish Hospital, Mayfield Clinic, Cincinnati, Ohio

function, therapies preceding SRS, WHO grade, and imaging characteristics of perioptic meningiomas.

Stereotactic Radiosurgery Technique

SRS was performed following standard techniques using Gamma Knife units (Elekta AB, Stockholm, Sweden) using frame-based or frameless approach for hypofractionated SRS or when stereotactic frame application was not technically possible. The decision to use single-fraction or hypofractionated SRS techniques was made at the discretion of the treating team. Biologically effective dose (BED) was calculated for proper comparison of different fractionation regimens using α/β ratio of 3.^{26,27}

Clinical and Radiographic Follow-up

Imaging and clinical follow-up was performed at 3- to 6-mo intervals for the first 2 yr after SRS, with annual follow-up thereafter. Volume of perioptic meningiomas at latest imaging follow-up was compared to pre-SRS imaging data and was categorized as stable (within 20% change), regression ($>20\%$ decrease), or progression ($\geq 20\%$ increase).^{28,29} Time to tumor volume change and death were recorded.

Visual follow-up was obtained through a combination of ophthalmic visual field examination and outpatient clinic visits. Formal visual field testing was performed as indicated and per the protocol of the individual sites. Visual status change at last follow-up was categorized by the treating team as not changed, improved, or declined. SRS-related adverse events were categorized according to the Radiation Therapy Oncology Group Central Nervous System toxicity criteria.³⁰

Statistical Analyses

Statistical analyses were performed with the IBM Statistical Package for the Social Sciences Statistics for Windows, version 25.0 (IBM Corp, Armonk, New York). Progression-free survival (PFS) was defined as interval (in months) from SRS for perioptic meningioma to last imaging follow-up or MRI documented progression of an index tumor, whichever occurred first. Time to visual decline was defined as interval (in months) from SRS for perioptic meningioma to deterioration of visual function (as deemed by the treating team) on formal ophthalmologic examination or clinical examination or last follow-up. The association of clinical and SRS factors with PFS and time to visual change was first investigated using the Kaplan-Meier method, and univariate and multivariate Cox regression analyses, with significant predictors in univariate analyses being entered in multivariate Cox regression analysis models. BED, margin dose, and maximal dose to optic apparatus were considered separately in regression models because they are inter-related. Results of Cox regression analysis are presented as hazard ratio (HR), 95% CI, and *P* value.

RESULTS

A total of 438 patients underwent SRS for perioptic meningiomas (Table 1; Figure 1). The majority of SRS-treated tumors were clinoidal (31%) and tuberculum sella (31%) meningiomas. A total of 153 patients (35%) had histories of at least 1 resection surgery of the perioptic meningioma. Pathology reports were available for 126 patients: 124 patients were diagnosed with WHO grade I meningiomas and 2 with WHO grade II meningiomas.

TABLE 1. Demographic and Clinical Characteristics of the Study Patients (n = 438)

Gender, n (%)	
Men	99 (23%)
Women	339 (77%)
Age (yr)	
Median [range]; mean ± SD	51 [15-83]; 51.13 ± 12.28
Karnofsky Performance Index before SRS (score)	
Median [range]; mean ± SD	90 [50-100]; 85.31 ± 13.97
Data not reported	244 (56%)
Pre-SRS visual deficit, n (%)	
Yes	257 (59%)
No	181 (41%)
Other presenting symptoms, n^a	
Headache	85
Diplopia	43
Ptosis	41
Incidental	35
Seizure	18
Other	62
Duration of symptoms (mo)	
Median [range]; mean ± SD	10 [0-240]; 19.60 ± 30.23
Unknown or data not available	71 (16%)
Pre-SRS endocrinopathy, n (%)	
None	412 (94%)
Hypothyroidism	15 (3%)
Estrogen/testosterone deficiency	3 (1%)
Diabetes insipidus	1 (0%)
Not reported	7 (2%)
Nearest distance to the optic apparatus (mm)	
Median [range]; mean ± SD	0 [0-2.3]; 0.36 ± 0.67
In direct contact with optic pathway	328 (75%)
Meningioma principal location, n (%)	
Clinoid	191 (44%)
Tuberculum sella	136 (31%)
Sphenoid wing	31 (7%)
Planum sphenoidale	17 (4%)
Clival/petroclival	15 (3%)
Parasellar	10 (2%)
Suprasellar	8 (2%)
Intraorbital	4 (1%)
Intrasellar	2 (1%)
Optic sheath	1 (0%)
Temporal pole	1 (0%)
Frontobasal	1 (0%)
Optic nerve sheath	1 (0%)
Not specified/other	8 (2%)
Other meningiomas, n (%)	77 (8%)
Index meningioma surgery before SRS, n (%)	153 (35%)
Number of prior resections, n (%)	
1	121 (79%)
2	28 (18%)
3	3 (2%)
4	1 (1%)

TABLE 1. Continued

Type of prior resection, n (%)	
Gross total resection	21 (14%)
Subtotal resection	120 (79%)
Biopsy	9 (6%)
Data not available	2 (1%)
Interval between surgery and SRS (mo)	
Median [range]; mean ± SD	9 [1-246]; 28.32 ± 44.57
Meningioma WHO grade, n (%)	
I	124 (28%)
II	2 (1%)
No pre-SRS surgery or data not available	312 (71%)
Histological type of index meningioma, n (%)	
Meningothelial	30 (7%)
Transitional	28 (6%)
Psammomatous	10 (2%)
Fibroblastic	5 (1%)
Mixed transitional and fibroblastic	5 (1%)
Angiomatous	1 (0.2%)
Microcystic	1 (0.2%)
Secretory	1 (0.2%)
Atypical	1 (0.2%)
No pre-SRS surgery or data not available	356 (81%)
Pre-SRS fractionated radiation therapy, n (%)	
Pre-SRS radiation therapy dose (Gy)	10 (2%)
Median [range]; mean ± SD	45 [13-60]; 40.42 ± 18.15
Data not available	4 (40%)
Pre-SRS radiation therapy number of fractions	
Median [range]; mean ± SD	17 [1-30]; 15.67 ± 12.21
Data not available	4 (40%)

SD, standard deviation.

^aTotal number does not add up to 438 because some patients had more than 1 presenting symptom.

SRS Characteristics

The majority of patients underwent single-fraction SRS (92.5%; Table 2). Treatment volumes and shortest distance to the optic apparatus were similar in patients treated using single-session vs hypofractionated SRS (*P* values ≥ .65). The median treatment volume was 8.01 cm³ (range: 0.130-57.3 cm³). Median marginal prescription dose for single-fraction SRS was 12 Gy (range: 7-18 Gy). Median maximal radiation dose to any portion of the optic apparatus was 8.50 Gy (range: 2-23 Gy). In total, 3 out of 4 patients who received maximal radiation dose to the optic apparatus of >16 Gy were treated using hypofractionated approach and 1 patient was blind on the ipsilateral eye before SRS. Patients who received ≥10 Gy vs <10 Gy to the optic apparatus had smaller tumor volume (7.22 ± 5.51 cm³ vs 10.48 ± 9.02 cm³, *P* = .001) but similar distance to the optic apparatus (*P* = .63).

Downloaded from https://academic.oup.com/neurosurgery/advance-article/doi/10.1093/neuros/nyaa544/6105224 by Serials Periodicals user on 26 January 2021

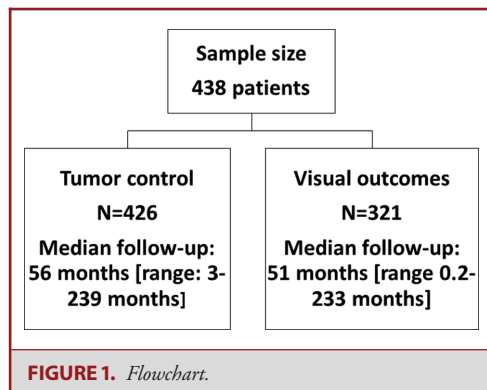


TABLE 2. SRS Characteristics of the Study Patients

Parameters	
Number of SRS fractions	
Single	405 (92.5%)
2	1 (0.2%)
3	6 (1.4%)
4	15 (3.4%)
5	10 (2.3%)
Data not available	1 (0.2%)
Treatment volume (cm³)	
Median [range]; mean ± SD	8.01 [0.130-57.3]; 9.78 ± 8.53
Number of isocenters	
Median [range]; mean ± SD	14 [1-54]; 16.55 ± 9.60
Margin tumor dose for single-fraction SRS (Gy)	
Median [range]; mean ± SD	12 [7-18]; 11.94 ± 1.33
BED (Gy)	
Median [range]; mean ± SD	60 [23.3-101.3]; 58.20 ± 12.17
Maximal tumor dose (Gy)	
Median [range]; mean ± SD	24 [8-48]; 23.49 ± 4.52
Maximal BED to optic apparatus (Gy)	
Median [range]; mean ± SD	36 [5.3-101.3]; 34.07 ± 13.26
Maximal dose to optic apparatus	
Median [range]; mean ± SD	8.50 [2-23]; 8.63 ± 2.08
Maximal dose to optic nerve (Gy)	
Median [range]; mean ± SD	8.30 [2-19]; 8.25 ± 1.99
Maximal dose to optic chiasm (Gy)	
Median [range]; mean ± SD	7.90 [1-21]; 7.49 ± 2.06
Maximal dose to optic tract (Gy)	
Median [range]; mean ± SD	6.30 [0-15]; 6.00 ± 2.02

SD, standard deviation.

Tumor Control

Post-SRS imaging follow-up was available for 426 patients and median duration was 56 mo (range: 3-239 months) (Table 3). The majority of perioptic meningiomas remained stable or regressed, and 33 patients (8%) experienced radiological progression at median interval from SRS to progression of 94 mo (range: 12-233 mo).

TABLE 3. Imaging Follow-up

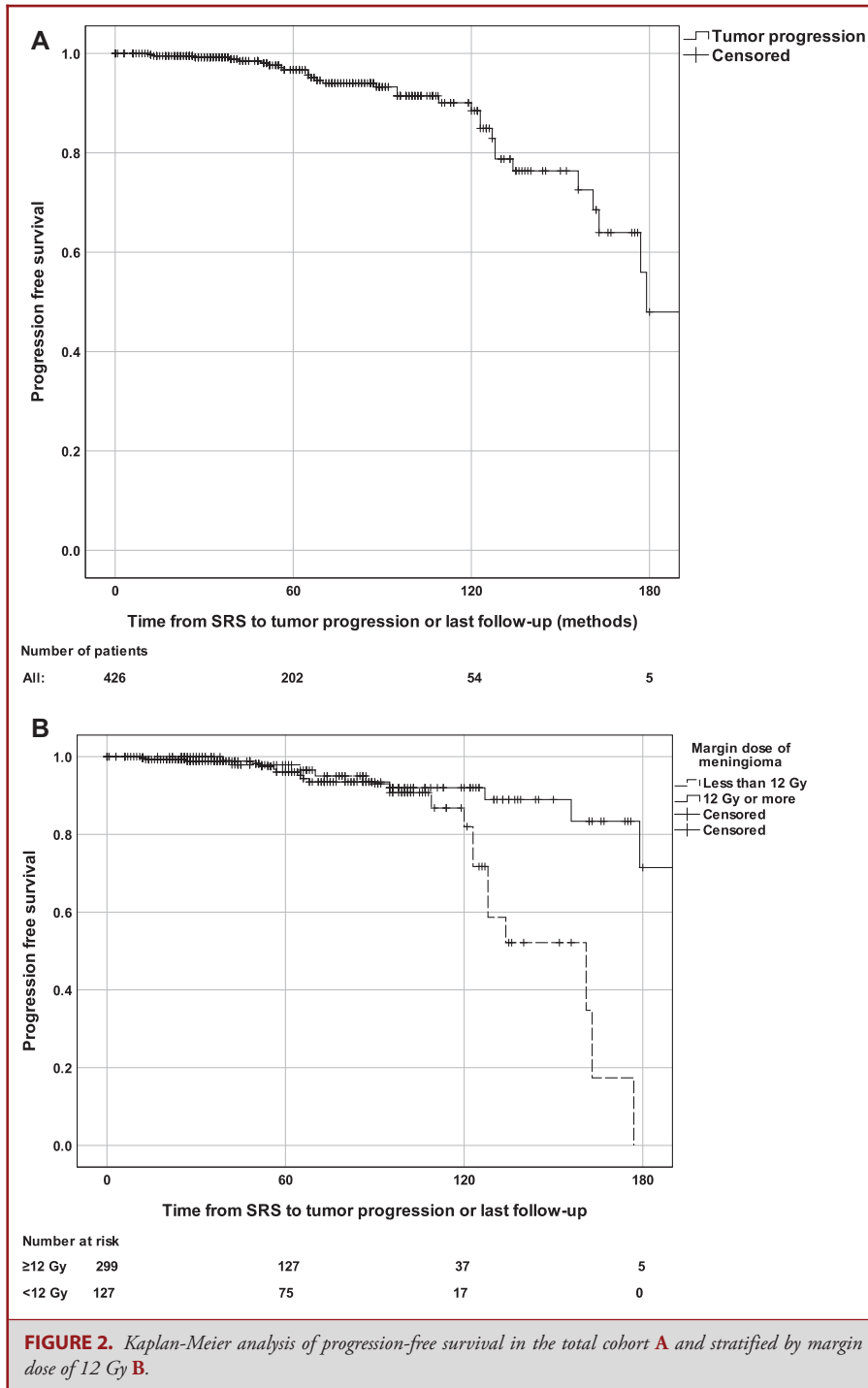
Characteristic	
Available data, n (%)	426
Imaging follow-up duration (mo)	
Median [range]; mean ± SD	55.6 [3.15-239]; 65.19 ± 43.02
Imaging outcomes at last follow-up, n (%)	
Stable	215 (51%)
Regression	178 (42%)
Progression	33 (8%)
Time to progression (mo)	
Median [range]; mean ± SD	94.07 [11.74-233.34]; 103.74 ± 56.34
Time to regression (mo)	
Median [range]; mean ± SD	64.85 [3.18-191.18]; 70.24 ± 40.87

SD, standard deviation.

Actuarial PFS rates at 5 and 10 yr after the SRS were 96% and 89%, respectively (Figure 2A). PFS was significantly shorter in patients treated with a tumor prescription dose of >12 Gy when compared to ≥12 Gy ($P = .024$; Figure 2B). In univariate Cox regression analysis, tumor prescription dose of ≥12 Gy (vs <12 Gy) ($P = .003$), BED ($P = .002$), the use of single-fraction SRS (vs hypofractionated SRS) ($P = .048$), and a greater maximal tumor radiation dose ($P = .015$) were associated with decreased risk of tumor progression, while pre-SRS radiation therapy ($P = .021$) and pre-SRS visual deficit ($P = .031$) were associated with increased perioptic meningioma progression risk (Table 4). In multivariate Cox regression analysis, prescription dose of ≥12 Gy (HR: 0.310 95% CI [0.141-0.679], $P = .003$), BED of ≥60 Gy (HR: 0.310 95% CI [0.141-0.679], $P = .003$), and single-fraction SRS (HR: 0.078 95% CI [0.016-0.395], $P = .002$) remained associated with lower risk for post-SRS progression. When considering only patients who underwent single-session radiosurgery (n = 405), in multivariate Cox regression analysis prescription dose of ≥12 Gy (HR: 0.323 95% CI [0.147-0.708], $P = .005$), BED of ≥60 Gy (HR: 0.323 95% CI [0.147-0.708], $P = .005$), and previous radiotherapy (HR: 24.603 95% CI [2.735-221.3], $P = .004$) remained associated with lower risk for tumor progression.

Visual Outcomes

Post-SRS visual outcomes were evaluated in 321 patients, with median duration of post-SRS visual follow-up of 51 mo (range: 0.2-233 mo) (Table 5). In the majority of patients visual status at last follow-up visit was not changed (60%) or improved (30%) when compared to pre-SRS function. In total, 4 (1%) patients with pre-SRS visual decline experienced new blindness in the ipsilateral eye after the SRS. A total of 31 (10%) patients experienced visual function decline after SRS at median interval from SRS of 52 mo (range: 3-152 mo). A total of 13 of those



patients (42%) experienced tumor radiological progression while the remaining did not. Pre-SRS visual impairment (absent vs present) was associated with visual function stabilization (94% vs 45%), improvement (0% vs 44%), and decline (13% vs 11%) at last post-SRS follow-up ($P < .001$).

Actuarial rates of visual decline at 5 and 10 yr following SRS were 9% and 21%, respectively (Figure 3A). Patients who received a maximal dose of ≥ 10 Gy vs < 10 Gy to the optic apparatus had greater actuarial visual decline rates at 5 yr (18% vs 7%) and 10 yr (46% vs 15%) after the SRS ($P = .034$).

TABLE 4. Predictors of Progression-Free Survival (n = 429)

Predictors	Univariate	Multivariate
Margin tumor prescription dose ≥ 12 Gy (vs < 12 Gy)	HR = 0.306 95% CI [0.140-0.670], $P = .003$	HR = 0.310 95% CI [0.141-0.679], $P = .003^a$
BED ≥ 60 Gy (vs < 60 Gy)	HR = 0.291 95% CI [0.135-0.624], $P = .002$	HR = 0.310 95% CI [0.141-0.679], $P = .003^a$
Single-fraction SRS (vs hypofractionated)	HR = 0.148 95% CI [0.032-0.692], $P = .048$	HR = 0.078 95% CI [0.016-0.395], $P = .002$
Maximal tumor dose (Gy)	HR = 0.909 95% CI [0.842-0.981], $P = .015$	$P = .076$
Dose to optic apparatus (Gy)	$P = .231$	–
Distance to optic apparatus (mm)	$P = .755$	–
Tumor volume (cm ³)	$P = .854$	–
Pre-SRS radiation therapy	HR = 11.222, 95% CI [1.1430-88.060], $P = .021$	$P = .063$
Pre-SRS surgery	$P = .371$	–
Pre-SRS visual deficit	HR = 2.560 [1.087-6.028], $P = .031$	$P = .133$
Age (yr)	$P = .741$	–
Gender	$P = .793$	–

SD, standard deviation.

^a – separate multivariate Cox regression models adjusted for significant predictors in univariate analyses.**TABLE 5. Visual Outcomes**

Visual follow-up	
N	321
Follow-up duration (mo)	
Median [range]; mean \pm SD	50.86 [0.2-233.34]; 60.23 \pm 4.58
Outcome at last follow up, n (%)	
All patients (n = 321)	
No change	196 (61%)
Improved	94 (29%)
Declined	31 (10%)
Pre-SRS visual impairment (n = 212)	
No change	95 (45%)
Improved	93 (44%)
Declined	24 (11%)
No pre-SRS visual impairment (n = 109)	
No change	102 (94%)
Improved	0 (0%)
Declined	7 (13%)
Time to visual decline ^a	
Median [range]; mean \pm SD	52.00 [0.2-133.0]; 49.92 \pm 39.42
Time to visual improvement ^a	
Median [range]; mean \pm SD	54.62 [3-151.7]; 62.34 \pm 37.47

SD, standard deviation.

^aTime to vision change or last formal visual field testing or clinical follow-up.

(Figure 3B). Maximal radiation dose to the optic apparatus of ≥ 10 Gy ($P = .03$), maximal BED of > 36 Gy ($P = .03$), and tumor progression ($P < .001$) were associated with greater risk of visual decline (Table 6). In multivariate Cox regression, maximal dose to optic apparatus of ≥ 10 Gy (HR = 2.370 95% CI [1.086-5.172], $P = .03$), BED of > 36 Gy (HR = 2.370 95% CI

[1.086-5.172], $P = .03$), and tumor progression (HR = 4.340 95% CI [2.070-9.097], $P < .001$) were associated with greater risk for post-SRS visual decline. In patients who underwent single-session SRS (n = 304), maximal dose to the optic apparatus of ≥ 10 Gy (HR = 2.318 95% CI [1.062-5.058], $P = .04$), BED to the optic apparatus of > 36 Gy (HR = 2.318 95% CI [1.062-5.058], $P = .04$), and tumor progression (HR = 2.322 95% CI [2.062-9.061], $P < .001$) remained associated with visual decline.

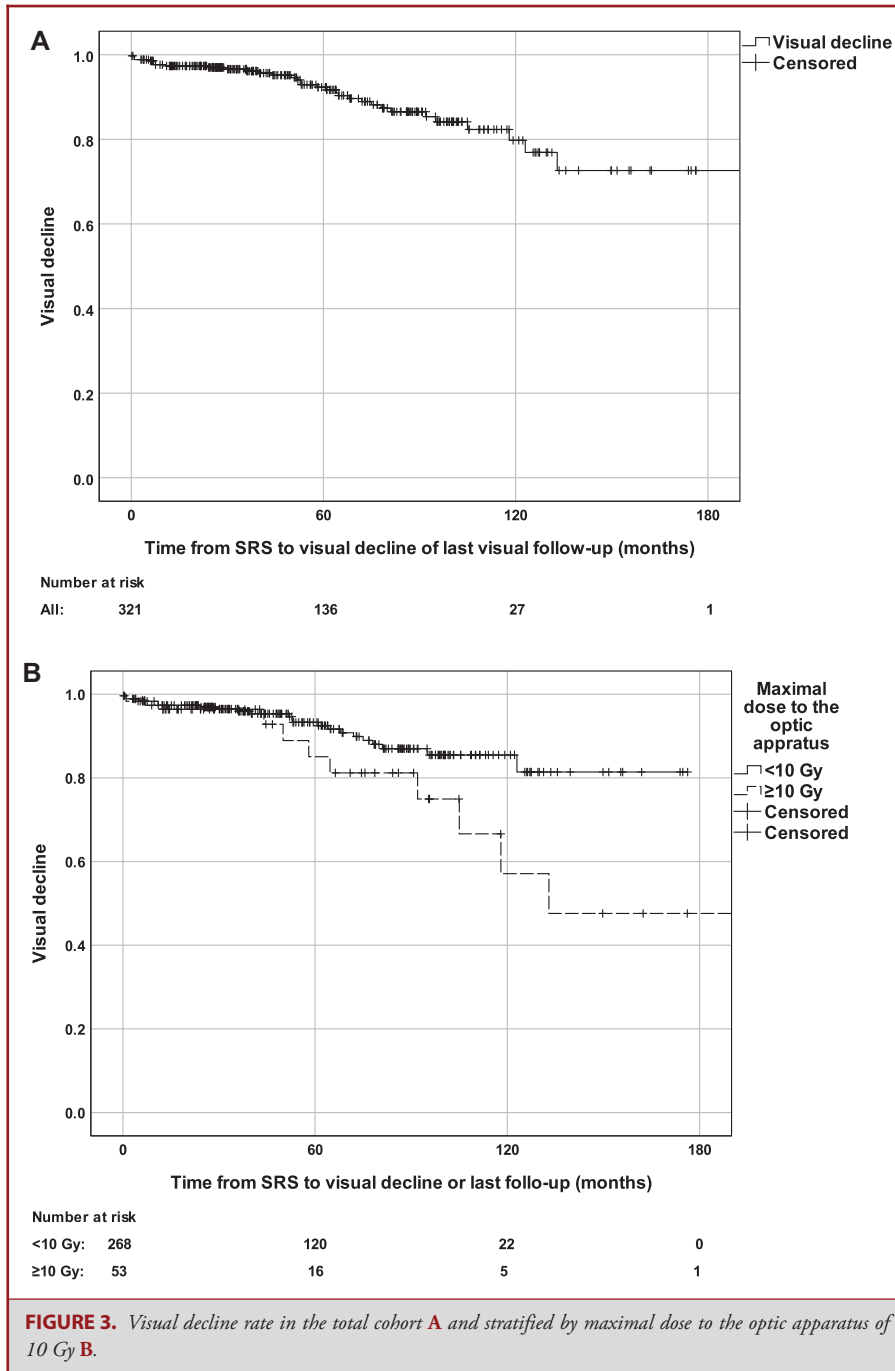
DISCUSSION

Key Results

Treatment with SRS was associated with durable control of perioptic meningiomas in the majority of patients. Marginal prescription dose of 12 Gy or greater and the use of single-fraction SRS were associated with better control of perioptic meningiomas. Visual status remained stable or improved in the vast majority of patients. Visual decline was uncommon after SRS, and was associated with a maximal dose to the optic apparatus of 10 Gy or greater and radiological tumor progression.

Interpretation

During a median post-SRS imaging follow-up of 56 mo, 8% of patients experienced radiological progression. In the majority of patients, perioptic meningiomas remained stable or regressed. Long-term control rate of perioptic meningiomas in our multi-institutional series was comparable to previously published SRS experiences for perioptic meningiomas.^{7,13} CyberKnife (Accuray) cooperative study that included 167 perioptic meningiomas treated with multisession SRS (25 Gy in 5 fractions) reported 8-yr PFS of 90%.⁷ Adler et al treated 49 perioptic tumors (27 meningiomas) with multisession CyberKnife SRS, and 94% of patients experienced disease stabilization or regression during a median imaging follow-up of 45 mo, with 2 meningiomas



progressing close to or within the treatment field.¹³ Long-term local control rates of perioptic meningiomas treated with SRS appears to be similar to local control rates of intracranial meningiomas of other anatomic locations that often exceed 85%.^{25,31} SRS offers reasonable long-term local control of perioptic meningiomas and should be considered for tumors residing in this surgically challenging anatomic location.

Single-session SRS and tumor prescription dose of 12 Gy or more were independently associated with better local control rate of perioptic meningiomas, underscoring the importance of adequate tumor dose prescription to achieve long-term tumor control. Indeed, adequate radiation dose is important for optimized local control of intracranial meningiomas.³²⁻³⁴ Commonly used margin doses for intracranial meningiomas are

TABLE 6. Predictors of Visual Outcomes

	Univariate	Multivariate
Visual decline		
Maximal dose to optic apparatus ≥ 10 Gy (vs < 10 Gy)	HR = 2.268 95% CI [1.044-4.927], $P = .039$	HR = 2.370 95% CI [1.086-5.172], $P = .03^a$
Maximal BED to the optic apparatus > 36 Gy (vs ≤ 36 Gy)	HR = 2.373 95% CI [1.086-5.181], $P = .030$	HR = 2.370 95% CI [1.086-5.172], $P = .03^a$
Single-fraction SRS (vs hypofractionated)	$P = .564$	–
Nearest distance to optic apparatus (mm)	$P = .860$	–
In contact with optic apparatus	$P = .857$	–
Pre-SRS surgery	$P = .140$	–
Pre-SRS radiation therapy	$P = .144$	–
Pre-SRS visual impairment	$P = .119$	–
Treatment volume (cm ³)	$P = .332$	–
Tumor radiological progression	HR = 4.186 95% CI [2.012-8.709], $P < .001$	HR = 4.340 95% CI [2.070-9.097], $P < .001$

SD, standard deviation.

^aSeparate multivariate Cox regression models adjusted for significant predictors in univariate analyses.

from 12 Gy to 16 Gy for WHO grade I meningiomas, 16 Gy to 20 Gy for WHO grade II meningiomas, and 18 Gy to 24 Gy for WHO grade III tumors.^{31,35-37} In our series, pathology results were available for 29% of the patients and a vast majority of meningiomas with available pathology results were WHO grade I tumors. Prescribed radiation dose of at least 12 Gy to the tumor margin should be attempted for perioptic meningioma, as long as doses to the optic apparatus remain below 10 Gy.

Differences in cell response to different irradiation doses have been documented.^{38,39} In our series, single-session SRS was associated with superior tumor control when compared to hypofractionated (2-5 fractions) SRS. Hypofractionated SRS allows preservation of surrounding normal tissues^{13,40,41} and excellent local tumor control with comparable safety profile.^{7,13,36,42,13} However, the number of patients treated with hypofractionated SRS in our cohort was small ($n = 32$) thus limiting generalizability of our findings to hypofractionated SRS.

Visual function remained stable or improved in the majority of patients, and only 10% of patients experienced post-SRS visual decline at median interval of 52 mo after the SRS. Visual outcomes in our multi-institutional cohort were comparable to previously reported visual outcomes of perioptic meningiomas treated using multisession SRS.^{7,13} Fractionated External Beam Radiation Therapy (EBRT) is traditionally considered for management of lesions in close contact with the optic apparatus,⁴³ and allows good local control rates of intracranial meningiomas that exceed 84%.⁴⁴⁻⁴⁶ However, treatment plans of EBRT are usually less conformal when compared to the SRS, and can be therefore associated with irradiation of the optic apparatus and other surrounding brain and intracranial structures, which can subsequently increase risk for long-term adverse events.⁴⁷⁻⁵¹ In our series, the vast majority of perioptic meningiomas were treated using single-session SRS, indicating that it is the preferred treatment approach in the majority of participating centers. We did not find an association of SRS fractionation schedule with

visual outcomes; however, hypofractionated SRS was associated with inferior local tumor control rate, suggesting that single-session SRS can potentially allow superior local tumor control without increasing risk of optic neuropathy, and should be therefore considered in the context of tumor volume, pre-SRS visual function and other relevant tumor and patient related parameters.

Maximal radiation dose to the optic apparatus of 10 Gy or more and tumor progression emerged as important independent predictors of visual deterioration. These findings underscore the importance of careful SRS dose planning and radiation dose consideration for perioptic meningiomas and adjacent optic structures because inadequate tumor prescription dose (< 12 Gy) can be associated with suboptimal long-term local tumor control that can subsequently impair visual function. Our findings confirm findings from prior studies showing that irradiation of the optic nerve with doses less than 10 Gy is safe and associated with minimal risk of optic neuropathy, with exponential increasing risk with radiation doses exceeding 10 Gy and 12 Gy.^{18,19,52} Tumor progression emerged as another important predictor of visual decline underscoring the importance of adequate tumor control in order to preserve visual function. Careful selection of radiation planning strategies (eg, use of curved posts) is imperative to optimize radiation dose to perioptic meningiomas and adjacent optic apparatus.

Limitations

Limitations of this study should be acknowledged. Approximately 2/3 of our patients did not have pathological confirmation and were diagnosed based on imaging findings. The possible impact of technological improvements in GK device and planning software, and learning curve is limited because all patients were managed at high-volume SRS centers and according to the prevailing guidelines.⁵³ BED was calculated using α/β ratio of 3 Gy, which is historically used for late responding tissues such as meningiomas; even small variations of α/β ratio could have

significant effect on BED.^{26,27,54} Objective assessment of visual function was not made in all patients at all times, thereby potentially limiting the validity of this component of the analysis. On the other hand, large sample size and long imaging and visual follow-up fortify reliability of our findings.^{7,13}

Generalizability

The majority of our patients were treated with a single-session SRS using GKRS thus limiting generalizability of our experience to other radiotherapy techniques.

CONCLUSION

SRS provides durable local control and a favorable rate of visual preservation for the majority of perioptic meningioma patients. Margin meningioma radiation dose of ≥ 12 Gy and single-fraction SRS are associated with improved tumor control, while radiation dose to the optic apparatus of ≥ 10 Gy and tumor progression are associated with increased risk for post-SRS visual decline.

Funding

This study did not receive any funding or financial support.

Disclosures

Dr Liscak is a consultant of Elekta. The other authors have no personal, financial, or institutional interest in any of the drugs, materials, or devices described in this article. Dr Cifarelli receives speaking honoraria from Carl Zeiss Meditech AG.

REFERENCES

- Eddleman CS, Liu JK. Optic nerve sheath meningioma: current diagnosis and treatment. *Neurosurg Focus*. 2007;23(5):E4.
- Risi P, Uske A, de Tribolet N. Meningiomas involving the anterior clinoid process. *Br J Neurosurg*. 1994;8(3):295-305.
- Hayhurst C, Teo C. Tuberculum sella meningioma. *Otolaryngol Clin North Am*. 2011;44(4):953-963.
- Al-Mefty O. Clinoidal meningiomas. *J Neurosurg*. 1990;73(6):840-849.
- Talacchi A, Hasanbelliu A, D'Amico A, et al. Long-term follow-up after surgical removal of meningioma of the inner third of the sphenoidal wing: outcome determinants and different strategies. *Neurosurg Rev*. 2020;43(1):109-117.
- Magill ST, Morshed RA, Lucas C-HG, et al. Tuberculum sellae meningiomas: grading scale to assess surgical outcomes using the transcranial versus transsphenoidal approach. *Neurosurg Focus*. 2018;44(4):E9.
- Marchetti M, Conti A, Beltramo G, et al. Multisession radiosurgery for perioptic meningiomas: medium-to-long term results from a CyberKnife cooperative study. *J Neurooncol*. 2019;143(3):597-604.
- Pechlivanis I, Wawrzyniak S, Engelhardt M, Schmieder K. Evidence level in the treatment of meningioma with focus on the comparison between surgery versus radiotherapy. A review. *J Neurosurg Sci*. 2011;55(4):319-328.
- Schick U, Dott U, Hassler W. Surgical management of meningiomas involving the optic nerve sheath. *J Neurosurg*. 2004;101(6):951-959.
- Bassiouni H, Asgari S, Sandalcioğlu IE, Seifert V, Stolke D, Marquardt G. Anterior clinoidal meningiomas: functional outcome after microsurgical resection in a consecutive series of 106 patients: clinical article. *J Neurosurg*. 2009;111(5):1078-1090.
- Giammattei L, Starnoni D, Levivier M, Messerer M, Daniel RT. Surgery for clinoidal meningiomas: case series and meta-analysis of outcomes and complications. *World Neurosurg*. 2019;129:e700-e717.
- Taha ANM, Erkmen K, Dunn IF, Pravdenkova S, Al-Mefty O. Meningiomas involving the optic canal: pattern of involvement and implications for surgical technique. *Neurosurg Focus*. 2011;30(5):E12.
- Adler JR, Gibbs IC, Puataweepong P, Chang SD. Visual field preservation after multisession CyberKnife radiosurgery for perioptic lesions. *Neurosurgery*. 2006;59(2):244-254; discussion 244-254.
- Dufour H, Muracciole X, Métellus P, Régis J, Chinot O, Grisoli F. Long-term tumor control and functional outcome in patients with cavernous sinus meningiomas treated by radiotherapy with or without previous surgery: is there an alternative to aggressive tumor removal? *Neurosurgery*. 2001;48(2):285-294; discussion 294-296.
- Cohen-Inbar O, Lee C, Schlesinger D, Xu Z, Sheehan JP. Long-term results of stereotactic radiosurgery for skull base meningiomas. *Neurosurgery*. 2016;79(1):58-68.
- Kondziolka D, Mathieu D, Lunsford LD, et al. Radiosurgery as definitive management of intracranial meningiomas. *Neurosurgery*. 2008;62(1):53-60; discussion 58-60.
- Minniti G, Amichetti M, Enrici RM. Radiotherapy and radiosurgery for benign skull base meningiomas. *Radiat Oncol*. 2009;4(1):42.
- Stafford SL, Pollock BE, Leavitt JA, et al. A study on the radiation tolerance of the optic nerves and chiasm after stereotactic radiosurgery. *Int J Radiat Oncol Biol Phys*. 2003;55(5):1177-1181.
- Milano MT, Grimm J, Soltys SG, et al. Single- and multi-fraction stereotactic radiosurgery dose tolerances of the optic pathways. published online: 2018. *Int J Radiat Oncol Biol Phys*. (doi:10.1016/j.ijrobp.2018.01.053).
- Conti A, Pontoriero A, Midilli F, et al. CyberKnife multisession stereotactic radiosurgery and hypofractionated stereotactic radiotherapy for perioptic meningiomas: intermediate-term results and radiobiological considerations. *Springerplus*. 2015;4:37.
- Bunevicius A, Kano H, Lee C-C, et al. Early versus late Gamma Knife radiosurgery for Cushing's disease after prior resection: results of an international, multicenter study. published online: February 21, 2020. *J Neurosurg*. (doi:10.3171/2019.12.JNS192836).
- El-Shehaby AMN, Reda WA, Abdel Karim KM, Emad Eldin RM, Nabeel AM. Single-session Gamma Knife radiosurgery for optic pathway/hypothalamic gliomas. *J Neurosurg*. 2016;125(Suppl_1):50-57.
- Kim M-S, Park K, Kim JH, Kim Y-D, Lee J-I. Gamma Knife radiosurgery for orbital tumors. *Clin Neurol Neurosurg*. 2008;110(10):1003-1007.
- Akyoldaş G, Hergünel ÖB, Yılmaz M, Şengöz M, Peker S. Gamma Knife radiosurgery for anterior clinoid process meningiomas: a series of 61 consecutive patients. *World Neurosurg*. 2020;133:e529-e534.
- Sheehan JP, Starke RM, Kano H, et al. Gamma Knife radiosurgery for sellar and parasellar meningiomas: a multicenter study. *J Neurosurg*. 2014;120(6):1268-1277.
- Vernimmen F, Slabbert JP. Assessment of the alpha/beta ratios for arteriovenous malformations, meningiomas, acoustic neuromas, and the optic chiasma. *Int J Radiat Biol*. 2010;86(6):486-498.
- Shrieve DC, Hazard L, Boucher K, Jensen RL. Dose fractionation in stereotactic radiotherapy for parasellar meningiomas: radiobiological considerations of efficacy and optic nerve tolerance. *J Neurosurg*. 2004;101(Suppl 3):390-395.
- Yang D-Y, Sheehan J, Liu Y-S, et al. Analysis of factors associated with volumetric data errors in Gamma Knife radiosurgery. *Stereotact Funct Neurosurg*. 2009;87(1):1-7.
- Chukwueke UN, Wen PY. Use of the Response Assessment in Neuro-Oncology (RANO) criteria in clinical trials and clinical practice. *CNS Oncol*. 2019;8(1):CNS28.
- Shaw E, Scott C, Souhami L, et al. Single dose radiosurgical treatment of recurrent previously irradiated primary brain tumors and brain metastases: final report of RTOG protocol 90-05. *Int J Radiat Oncol Biol Phys*. 2000;47(2):291-298.
- Sheehan JP, Williams BJ, Yen CP. Stereotactic radiosurgery for WHO grade I meningiomas. *J Neurooncol*. 2010;99(3):407-416.
- Ganz JC, Backlund E-O, Thorsen FA. The results of Gamma Knife surgery of meningiomas, related to size of tumor and dose. *Stereotact Funct Neurosurg*. 1993;61(Suppl 1):23-29.
- Meniai-Merzouki F, Bernier-Chastagner V, Geffrelot J, et al. Hypofractionated Stereotactic Radiotherapy for patients with intracranial meningiomas: impact of radiotherapy regimen on local control. *Sci Rep*. 2018;8(1):1-8.

34. Vera E, Iorgulescu JB, Raper DMS, et al. A review of stereotactic radiosurgery practice in the management of skull base meningiomas. *J Neurol Surg B Skull Base*. 2014;75(3):152-158.
35. Lee C-C, Trifiletti DM, Sahgal A, et al. Stereotactic Radiosurgery for benign (World Health Organization grade I) cavernous sinus meningiomas—International Stereotactic Radiosurgery Society (ISRS) practice guideline: a systematic review. *Neurosurgery*. 2018;83(6):1128-1142.
36. Cohen-Inbar O, Lee C-C, Sheehan JP. The contemporary role of stereotactic radiosurgery in the treatment of meningiomas. *Neurosurg Clin N Am*. 2016;27(2):215-228.
37. Ding D, Starke RM, Hantzmon J, Yen C-P, Williams BJ, Sheehan JP. The role of radiosurgery in the management of WHO grade II and III intracranial meningiomas. *Neurosurg Focus*. 2013;35(6):E16.
38. Garcia-Barros M, Paris F, Cordon-Cardo C, et al. Tumor response to radiotherapy regulated by endothelial cell apoptosis. *Science*. 2003;300(5622):1155-1159.
39. Nagle PW, Hosper NA, Barazzuol L, et al. Lack of DNA damage response at low radiation doses in adult stem cells contributes to organ dysfunction. *Clin Cancer Res*. 2018;24(24):6583-6593.
40. Barnett GH, Linskey ME, Adler JR, et al. Stereotactic radiosurgery—an organized neurosurgery-sanctioned definition. *J Neurosurg*. 2007;106(1):1-5.
41. Nguyen JH, Chen C-J, Lee C-C, et al. Multisession Gamma Knife radiosurgery: a preliminary experience with a noninvasive, relocatable frame. *World Neurosurg*. 2014;82(6):1256-1263.
42. Timmerman RD. An overview of hypofractionation and introduction to this issue of seminars in radiation oncology. *Semin Radiat Oncol*. 2008;18(4):215-222.
43. Bloch O, Sun M, Kaur G, Barani IJ, Parsa AT. Fractionated radiotherapy for optic nerve sheath meningiomas. *J Clin Neurosci*. 2012;19(9):1210-1215.
44. Onodera S, Aoyama H, Katoh N, et al. Long-term outcomes of fractionated stereotactic radiotherapy for intracranial skull base benign meningiomas in single institution. *Jpn J Clin Oncol*. 2011;41(4):462-468.
45. Milker-Zabel S, Zabel A, Schulz-Ertner D, Schlegel W, Wannemacher M, Debus J. Fractionated stereotactic radiotherapy in patients with benign or atypical intracranial meningioma: long-term experience and prognostic factors. *Int J Radiat Oncol Biol Phys*. 2005;61(3):809-816.
46. Soldà F, Wharham B, De Ieso PB, Bonner J, Ashley S, Brada M. Long-term efficacy of fractionated radiotherapy for benign meningiomas. *Radiother Oncol*. 2013;109(2):330-334.
47. Kiehna EN, Mulhern RK, Li C, Xiong X, Merchant TE. Changes in attentional performance of children and young adults with localized primary brain tumors after conformal radiation therapy. *J Clin Oncol*. 2006;24(33):5283-5290.
48. Jalali R, Gupta T, Goda JS, et al. Efficacy of stereotactic conformal radiotherapy vs conventional radiotherapy on benign and low-grade brain tumors: a randomized clinical trial. *JAMA Oncol*. 2017;3(10):1368-1376.
49. Haddy N, Mousannif A, Tukenova M, et al. Relationship between the brain radiation dose for the treatment of childhood cancer and the risk of long-term cerebrovascular mortality. *Brain*. 2011;134(5):1362-1372.
50. Appelman-Dijkstra NM, Kokshoorn NE, Dekkers OM, et al. Pituitary dysfunction in adult patients after cranial radiotherapy: systematic review and meta-analysis. *J Clin Endocrinol Metab*. 2011;96(8):2330-2340.
51. Chung CS, Yock TI, Nelson K, Xu Y, Keating NL, Tarbell NJ. Incidence of second malignancies among patients treated with proton versus photon radiation. *Int J Radiat Oncol Biol Phys*. 2013;87(1):46-52.
52. Leavitt JA, Stafford SL, Link MJ, Pollock BE. Long-term evaluation of radiation-induced optic neuropathy after single-fraction stereotactic radiosurgery. *Int J Radiat Oncol Biol Phys*. 2013;87(3):524-527.
53. Bunevicius A, Sheehan D, Lee Vance M, Schlesinger D, Sheehan JP. Outcomes of Cushing's disease following Gamma Knife radiosurgery: effect of a center's growing experience and era of treatment. published online: January 31, 2020. *J Neurosurg*. (doi:10.3171/2019.12.JNS192743).
54. Speckter H, Santana J, Miches I, et al. Assessment of the alpha/beta ratio of the optic pathway to adjust hypofractionated stereotactic radiosurgery regimens for perioptic lesions. *J Radiat Oncol*. 2019;8(3):279-289.

Neurosurgery Speaks! Audio abstracts available for this article at www.neurosurgery-online.com.

COMMENT

In this large retrospective multicenter study, the authors analyzed the safety and effectiveness of SRS for perioptic meningiomas located 3 mm or closer to the optic nerve or chiasm (mostly clinoidal and tuberculum sellae localizations). This article will most likely be dissected and maybe harshly criticized by many skull base surgeons. So far, SRS is very rarely used for this localization of meningioma. It should be noted that a third of the cases were recurrences after surgery, even if recurrences in this type of lesion are rare in expert hands. The challenge in this type of meningioma is not the tumor control, which is provided by SRS as showed with only 8% of tumor progression, similar to local control rates of intracranial meningiomas of other anatomical locations. Besides, as usual in series of meningiomas or vestibular schwannomas treated with SRS, it is difficult to interpret this result because we do not know the percentage of growing tumors and the growth rate.

In my opinion, the true challenge is to improve the visual function when impaired. It is not clear after reading the paper if SRS is very successful in this regard.

In any case, this is an important article for the future, because it shows that SRS provides durable tumor control and quite acceptable rates of vision preservation in perioptic meningiomas.

Michel Kalamarides
Paris, France